



# CAP Lung Cancer Medical Writers' Circle

## **Detecting Lung Cancer with Chest X-rays**

By Dr. Charles White

More than 200,000 Americans will be diagnosed with lung cancer this year, with only a small percentage of these patients diagnosed in earliest stages, when it is most treatable. The American Cancer Society estimated 222,520 patients were diagnosed with lung cancer in 2010 and more than 150,000 lost their battle to the disease. More people will die from lung cancer this year than breast, colon, and prostate cancers combined.

### **Lung Cancer Awareness and Funding**

While lung cancer is the leading cancer killer, it falls short on funding, research, and early detection screening programs. Lung cancer continues to be the least funded in dollars per death of the four major cancers. The following chart represents the research dollars the Department of Defense, the Centers for Disease Control and Prevention and the National Institute of Health spent in 2009 per death for respective types of cancers.<sup>1</sup>

Research Spending Per Death	
Breast	\$27,480
Prostate	\$11,336
Colon	\$6,590
Lung	\$1,249

Lung cancer continues to be plagued by the stigma associated with smoking. Cigarette smoking is only one of the risks associated with lung cancer. Approximately 15 percent of lung cancer patients are non-smokers. These patients, smoking and otherwise, deserve the same funding, screening, and community support as breast cancer and heart disease. Only through activism and associated funding have devastating diseases seen dramatic improvements in the effectiveness of treatments and in the benefits of early detection.

### **Early Detection**

According to the American Cancer Society (ACS) Cancer Facts & Figures, 2010, the five year survival rate of a lung cancer patient for all stages combined is 16 percent. Only 15 percent of lung cancer is diagnosed at the earliest and most treatable stage.

<sup>1</sup> ACS Cancer Facts & Figures, 2010 <http://www.cancer.org/Research/CancerFactsFigures/CancerFactsFigures/cancer-facts-and-figures-2010>

Detection at an early stage is difficult. Symptoms, such as persistent cough, chest pain, or shortness of breath, are not commonly present until the cancer has grown to a significant size. In fact, the detection of early stage lung cancer is typically a result of an asymptomatic patient receiving a chest X-ray or CT scan for an issue unrelated to lung cancer.

### **Making the Most Out of Chest X-rays**

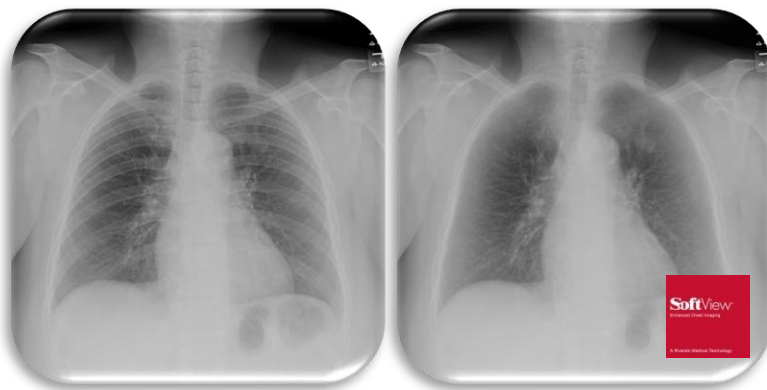
Known as the workhorse of the hospital, X-rays are used to detect and diagnose a constellation of different injuries and diseases, including lung cancer. However, chest X-rays are an underutilized source of information.

Most lung cancers, early- and late-stage, are detected using a traditional chest X-ray, due in large part to the frequent use of the chest x-ray. One out of every 500 to 1,000 chest X-rays reveals an unexpected lung nodule.<sup>2</sup>

Detection at an early stage is difficult. When the cancerous lung nodule is small, it can appear to merge into the patterns of other normal structures and may not be identified. In fact, approximately 30 percent of lung cancers are not detected, but a radiologist can see many of these cancers once they are pointed out.

The University of Maryland Medical Center is currently researching two new technologies that allow chest X-rays to become more effective and practical for detecting lung cancer in its earliest stages.

### **Soft Tissue Images: Seeing Beyond the Bone**



*Courtesy of Riverain Medical*

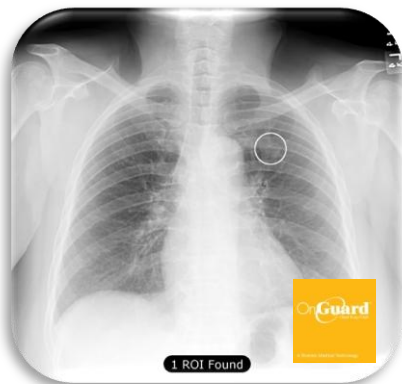**Before and After: Riverain Medical's SoftView technology uses advanced algorithms to suppress the bone in chest X-ray images, allowing radiologists to see the soft tissue behind the bone.**

<sup>2</sup> Andrews, Tina. (2010, March 23). *Characteristics of Benign Lung Nodules*. Retrieved from: <http://www.livestrong.com/article/85586-characteristics-benign-lung-nodules/>

Data have shown that 81 percent of missed lung cancers were partially obscured by ribs and clavicles.<sup>3</sup> New technologies are now available that lead to increased visibility of soft tissue on a chest X-ray.

Cleared by the FDA in March 2010, Riverain Medical's SoftView™ technology is a new image enhancement technology that increases clarity and improves detection of lung nodules. SoftView suppresses bones of the ribs and clavicle in a chest x-ray, utilizing an advanced software algorithm to provide a soft tissue image for digital chest X-rays. The technology allows radiologists to see the soft tissue behind the bone, resulting in more confident image interpretation. In fact, multi-reader studies show that the use of SoftView can improve the detection of nodules by 15 percent which is deemed statistically significant.

### Technology: Giving Radiologists a Second Set of Eyes



*Courtesy of Riverain Medical*

**Data demonstrates that radiologists who use Riverain Medical's OnGuard CAD technology for chest X-rays can detect up to 50 percent of missed lung nodules.**<sup>4,5</sup>

Computer-aided Detection (CAD) is a widely-used tool in mammography, breast MRI, virtual colonoscopy, chest X-rays, and lung CT. CAD technologies work as a second set of eyes to indicate areas that warrant a closer look.

Using an existing X-ray, OnGuard CAD technology automatically places markers around regions of the lung that may be early-stage cancer. The newest FDA approved version (June 2010) showed a significant reduction in false positive marks (73 percent reduction) while simultaneously achieving a 50 percent relative improvement in sensitivity to earlier versions. OnGuard can improve the detection of nodules and detect up to 50 percent of missed nodules.<sup>6,7</sup>

Studies have shown that with the early detection of lung cancer, five-year survivability rates can triple. Technologies are available that have the potential to make this early detection a reality.

<sup>3</sup> J. Austin (1992). *Radiology*. Vol. 182:1, 115-122.

<sup>4</sup> Riverain Medical. FDA PMA Clinical Trial 2009.

<sup>5</sup> C. White, T. Flukinger, J. Judy and J. Chen (2009). Use of a Computer-Aided Detection System to Detect Missing Lung Cancer at Chest Radiography. *Radiology*. 252: 273-281

<sup>6</sup> Riverain Medical. FDA PMA Clinical Trial 2009.

<sup>7</sup> C. White, T. Flukinger, J. Judy and J. Chen (2009). Use of a Computer-Aided Detection System to Detect Missing Lung Cancer at Chest Radiography. *Radiology*. 252: 273-281

## **About the Author**

Dr. Charles S. White, M.D. is the Professor of Radiology and Medicine and Vice Chairman of Radiology at the University of Maryland Medical Center. As head of thoracic imaging, he oversees a group of 6 radiologists as well as fellows and residents. He has multiple publications on the use of chest radiography and CT to diagnose lung cancer.